TREATING HEPATITIS C WITH BIOMAGNETISM

David Goiz Martínez1*† and Mario Salinas Soto1,2

*Correspondence:
drdavidgoiz@biomagnetismo.biz
1Departamento de Bioenergética, CIBM, Insurgentes 1865, 07020 México Distrito Federal,
MX Full list of author information is available at the end of the article
†Equal contributor

Resumen
El VHC es un virus de transmisión sanguínea que estaba previamente referido como no-A hepatitis / no-B. El VHC tiene siete genotipos, numerados 1-7.
El genotipo 1 es el más común en los EE.UU. El VHC entra al cuerpo a través de la sangre directa la exposición. Ataca a las células en el hígado, donde se multiplica (replica). Las causas del virus de la hepatitis C (VHC) es la inflamación del hígado y mata a las células del hígado. Hasta 75% de las personas inicialmente infectadas con el VHC puede llegar a desarrollar una infección crónica, y dentro de los primeros seis meses puede no ser detectado.
La mayoría de las personas con infección crónica por VHC no presentan síntomas y pueden llevar una vida normal. Sin embargo, en el 10-25% de las personas con enfermedades crónicas por VHC, progresan durante un período
de 10 a 40 años, y puede conducir a graves daños del hígado, como cirrosis (cicatrización) y cáncer de hígado.
Hoy en día, el VHC es la razón principal para trasplantes en los EE.UU. Actualmente no existe vacuna contra el VHC; Sin embargo, el tratamiento puede curar a la mayoría de la gente de VHC y hacer mas lenta la evolución de los daños.

Palabras Clave: Virus RNA, trasmisión, diagnóstico, Prevención.

Abstract
HCV is a blood-borne virus that was previously referred to as non-A/non-B hepatitis. HCV has seven genotypes, numbered 1–7.
Genotype 1 is the most common in the U.S.
HCV enters the body through direct blood exposure. The virus attacks cells in the liver, where it multiplies (replicates). HCV causes liver inflammation and kills liver cells. Up to 75% of people initially infected with HCV may become chronically infected; that is, the infection does not clear up within six months. Most people with chronic HCV do not experience symptoms and lead normal lives.
However, in 10–25% of cases, the disease progresses over a period of 10–40 years in people with chronic HCV and may lead to serious liver damage, cirrhosis (scarring), and liver cancer.
Today, HCV is the leading reason for liver transplants in the U.S. Currently there is no vaccine for HCV; however, treatment can cure
most people with HCV and stop or slow down the progression of the disease.

Keywords: virus RNA, transmission, diagnosis, prevention.

Introduction:

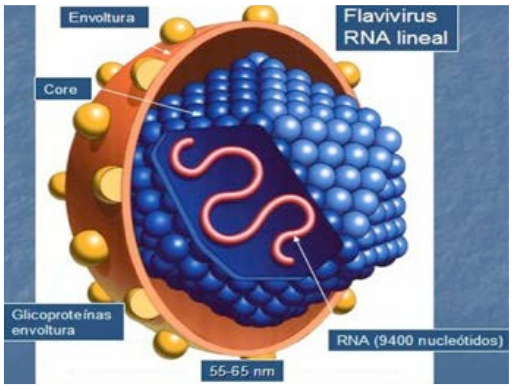

Hepatitis C is a viral infection of the liver caused by a RNA virus, a member of the Flaviviridae family and replicates itself in the liver.

Is spreads from one person to another through blood, after a syringe puncture or injury from a sharp object. Or if blood from a hepatitis C carrier comes into contact with a skin cut, as well as eye or mouth mucus.

Most people infected with hepatitis C do not experience any symptoms for many years. However, generally speaking Hepatitis C is a chronic disease, meaning that there is no cure.

David Goiz Martínez1*† and Mario Salinas Soto1,2

Persons at risk of contracting hepatitis C include:

- Those who use syringes for illegal drugs or share needles with someone that has hepatitis C.
- Those who have been on kidney dialysis for a long time.
- Those who come into contact with blood frequently at work (for example, health workers).
- Those having unprotected intercourse with a person that has hepatitis C.
- Babies born to a mother infected with hepatitis C.
- Persons that have been tattooed o have undergone acupuncture with needles that were not properly disinfected prior to use after being used on another person (the risk level is very low when it is done by a licensed person performing the tattooing or acupuncture).
- Organ transplant recipients who received an organ from a donor with hepatitis C.
- Those who share personal hygiene products such as razor blades, shaving razors or tooth brushes with someone that has hepatitis C (less common cause).
- Those who receive a blood transfusion.

Statistics

Hepatitis C is considered a major public health problem that requires national and international attention. The chronic disease caused by HCV in most cases runs its course undetected, without symptoms, which is why it's so important in terms of epidemiology. According to estimates, there are close to 170 million infected persons in the world. Global prevalence of HCV infection is estimated to be 2.2% globally. In Mexico it is reported that prevalence is 1% to 1.9%, similar to that reported in the U.S. Based on a conservative model, it could be said that 1.2 million persons in Mexico are infected with HCV.

Symptoms

Persons recently infected with hepatitis C experience no symptoms. Some show signs of jaundice which eventually disappears. The chronic infection generally does not cause any symptoms but can cause fatigue, skin disorders and other problems.

There are several symptoms that might appear during the illness, which include pain in the upper right quadrant of the abdomen, abdominal swelling due to fluids (ascites), discolored or clay-colored feces, Choluria, fatigue, fever, itchiness, loss of appetite, nausea and vomiting.

Diagnosis

Blood tests are done to verify the presence of hepatitis C: Enzyme immune-analysis to detect hepatitis C fighting antibodies; RNA test for hepatitis C to measure the virus load levels.

Genetic tests are done to verify the genotype of the hepatitis C. There are 6 types of virus (genotypes 1 through 6) and more than 50 subtypes. The genotype 1b is the most common subtype in the world. The following tests are done to verify and monitor the liver damage caused by hepatitis C:

- Albumin level
- Liver function tests
- Prothrombim time
- Liver biopsy

Treatment

A combination of Peginterferon and Ribavirin are usually used. These medication's objective is to help the body rid itself of the virus, as well as reduce the risk of liver cancer and cirrhosis, both of which can result after a prolonged HCV infection. Interferon suppresses the hematopoiesis and patients frequently exhibit cytophenia (a decrease in blood cells). Ribavirin can suppress erythropoiesis which can aggravate the level of anemia. So another medication is used, Erythropoietin, which helps stimulate erythrocyte production and reduce the need of a blood transfusion.

A good outcome to treatment comes about when the virus is no longer detected in the blood after treatment.

Prevention

The measures that can be adopted to avoid transmittal of hepatitis C from person to person include:

- Healthcare workers must take the necessary precautions when handling blood.
- People should not share needles with anyone else.
- People should avoid tattoos, body piercings and should not be treated with acupuncture by someone who is not a licensed practitioner.
- People shouldn't share personal hygiene things such as shaving razors or toothbrushes with others.
- People should take the necessary precautions when having sexual intercourse.

Hepatitis C virus is not passed on through casual contact, such as shaking hands, kissing, coughing and sneezing, breastfeeding, sharing eating utensils or drinking cups.

CLINICAL CASE

David Goiz Martínez1*† and Mario Salinas Soto1,2

58 year old female client born and residing in Mexico City who was diagnosed with hepatitis C, on October 2013, with a positive viral panel, genotype 1b. Client says she is undergoing treatment and taking 2 tablets of 200 mg Ribavirin every 8 hours, receiving vaccine type shots (not specified) with two doses. History and important information, underwent several surgical procedures including a C-section 33 years ago, hysterectomy and left oophorectomy 8 years ago due to uterine fibroids and polycystic ovary syndrome. Had Human papilloma virus without showing lesions 10 years ago. Underwent appendectomy 15 years ago. Blood transfusions during surgery. Donor was a bloodline relative that was unaware of having hepatitis C. Client does not know how many packs of red cells were used, but there was no adverse reaction to procedure. In addition, client says she has received acupuncture treatment for 7 years.

Biomagnetic Pair Scan

At the first Biomagnetism visit on January 21, 2014, the client is asymptomatic, conscious, alert, and stable in all three areas, does not exhibit characteristic facies, has an adequate hydrolytic and nutritional level, has good skin color and shows no impairment in gait. Included here are the viral load test and genotyping tests done on October 28, 2013 (Image 1) and complete blood count test done on January 2014 (Image 2). During the scan, the following pairs were found:

Biomagnetic Pair Scanning Technique - Scan 1 (Bioenergetics)

	Negative (-)	Positive (+)	DMP
BP 1	Liver	Right Kidney	2cm
BP 2	Liver	Liver	2cm
BP 3	Inner ear	Inner ear	2cm
BP 4	Supraspinatus	Supraspinatus	2cm
BP 5	Post pineal	Bladder	2cm
BP 6	Sigmoid	Rectum	2cm
BP 7	Lesser Trochanter	Lesser Trochanter	2cm
BP 8	Kidney	Kidney	2cm
BP 9	Lumbar cyst		2cm

Table 1 Taken from office visit

David Goiz Martínez1*† and Mario Salinas Soto1,2

Image 1 Client's tests

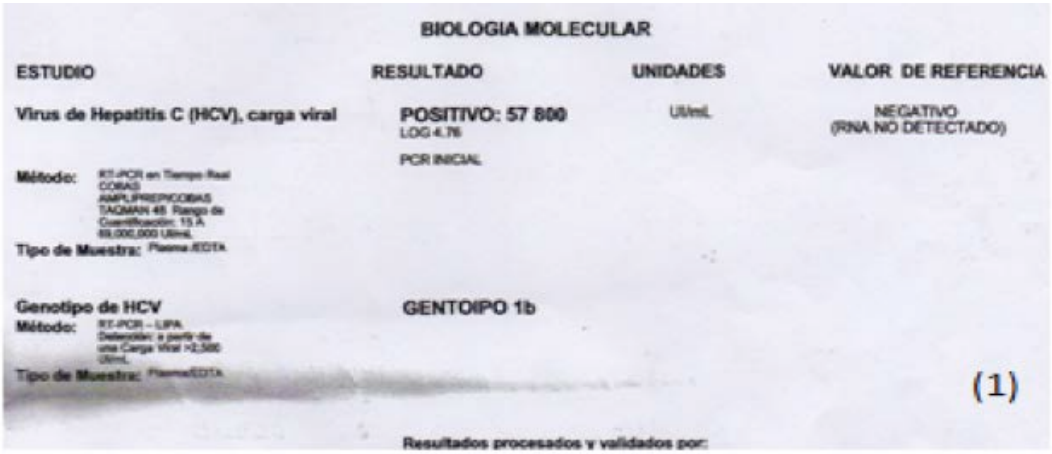

BIOLOGIA MOLECULAR

ESTUDIO	RESULTADO	UNIDADES	VALOR DE REFERENCIA
Virus de Hepatitis C (HCV), carga viral	POSITIVO: 57 800 LOG 4.76 PCR INICIAL	UI/mL	NEGATIVO (RNA NO DETECTADO)
Método: RT-PCR en Tiempo Real COBAS AMPLIPREP/COBAS TAQMAN 48. Rango de Cuantificación: 15 A 69,000,000 UI/mL			
Tipo de Muestra: Plasma/EDTA			
Genotipo de HCV	GENTOIPO 1b		
Método: RT-PCR – LIPA. Detección: a partir de una Carga Viral >2,500 UI/mL			
Tipo de Muestra: Plasma/EDTA			

(1)

Resultados procesados y validados por:

Image 2 Client's tests

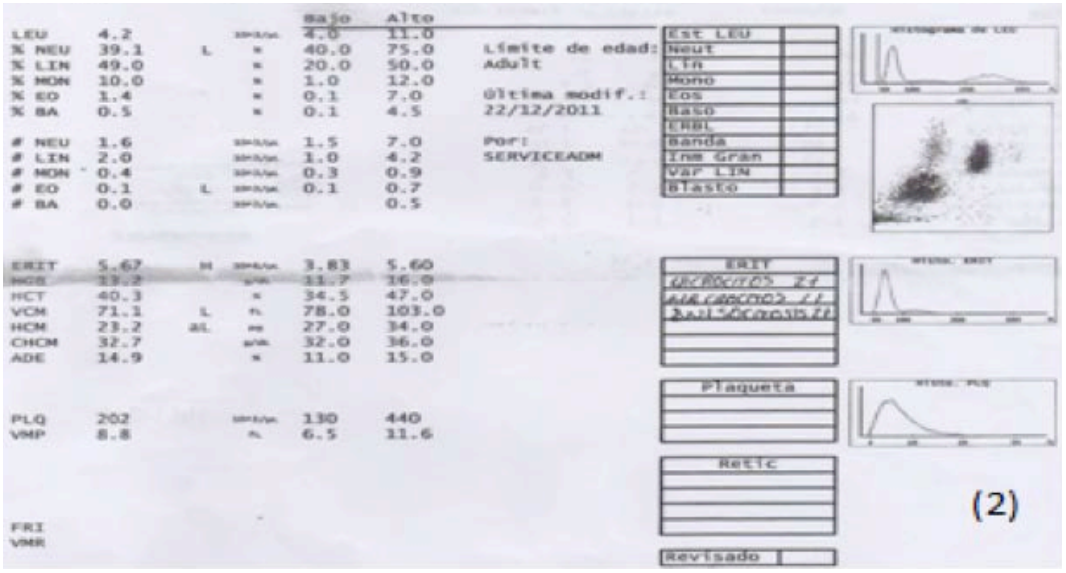

			Bajo	Alto	
LEU	4.2		4.0	11.0	
% NEU	39.1	L	40.0	75.0	Límite de edad:
% LIN	49.0		20.0	50.0	Adult
% MON	10.0		1.0	12.0	
% EO	1.4		0.1	7.0	Última modif.:
% BA	0.5		0.1	4.5	22/12/2011
# NEU	1.6		1.5	7.0	Por:
# LIN	2.0		1.0	4.2	SERVICEADM
# MON	0.4		0.3	0.9	
# EO	0.1	L	0.1	0.7	
# BA	0.0			0.5	
ERIT	5.67	H	3.83	5.60	
HGB	13.2		11.7	16.0	
HCT	40.3		34.5	47.0	
VCM	71.1	L	78.0	103.0	
HCM	23.2	AL	27.0	34.0	
CHCM	32.7		32.0	36.0	
ADE	14.9		11.0	15.0	
PLQ	202		130	440	
VMP	8.8		6.5	11.6	
FRI					
VMR					

Est LEU: Neut, Lin, Mono, Eos, Baso, ERBL, Banda, Inm Gran, VAP LIN, Blasto

ERIT

Plaqueta

Retic

Revisado

(2)

At the second scan done on February 1st, 2014, client reports not having a reaction after the first treatment and claims to be asymptomatic. At this treatment client confirms having taken first dose of interferon alpha-2A in weekly treatment. The following pairs were found:

Biomagnetic Pair Scanning Technique - Scan 2 (Bioenergetics)

	Negative (-)	Positive (+)	DMP
BP 1	Liver	Right Kidney	2cm
BP 2	Liver	Liver	2cm
BP 3	Diaphragm	Diaphragm	2cm
BP 4	Post pineal	Bladder	2cm
BP 5	Occipital	Occipital	2cm

Table 2 Taken from office visit

Third scan is done on February 17th, 2014. Client exhibits asthenia and adynamia. The following biomagnetic pairs were found:

Biomagnetic Pair Scanning Technique - Scan 3 (Bioenergetics)

	Negative (-)	Positive (+)	DMP
BP 1	Liver	Spleen	2cm
BP 2	Spleen	Spleen	2cm
BP 3	Kidney	Kidney	2cm
BP 4	Right shoulder	Cardia	2cm

Table 3 Taken from office visit

Fourth scan is done on February 22, 2014. There was an improvement in symptoms. Client exhibits influenza illness, which is in its third day, and reports not taking medication to treat it. The following pairs were found:

Biomagnetic Pair Scanning Technique - Scan 4 (Bioenergetics)

	Negative (-)	Positive (+)	DMP
BP 1	Pericardium	Pericardium	2cm
BP 2	Vagina	Vagina	2cm
BP 3	Mastoid	Mastoides	2cm
BP 4	Supraspinatus	Supraspinatus	2cm
BP 5	Bladder	Bladder	2cm
BP 6	Kidney	Kidney	2cm

Table 4 Taken from office visit

Fifth scan is done on March 14th, 2014. Client reports improvement of symptoms and is asymptomatic at the time. Provides new test results dated February 25th (Image 3), doctor has suspended interferon. The following pairs were found:

Biomagnetic Pair Scanning Technique - Scan 5 (Bioenergetics)

	Negative (-)	Positive (+)	DMP
BP 1	Liver	Right Kidney	2cm
BP 2	Liver	Left Kidney	2cm
BP 3	Post pineal	Bladder	2cm
BP 4	Pericardio	Pericardium	2cm
BP 5	Cardias	Appendix	2cm
BP 6	Kidney	Kidney	2cm

Table 5 Taken from office visit

Image 3 Client's tests

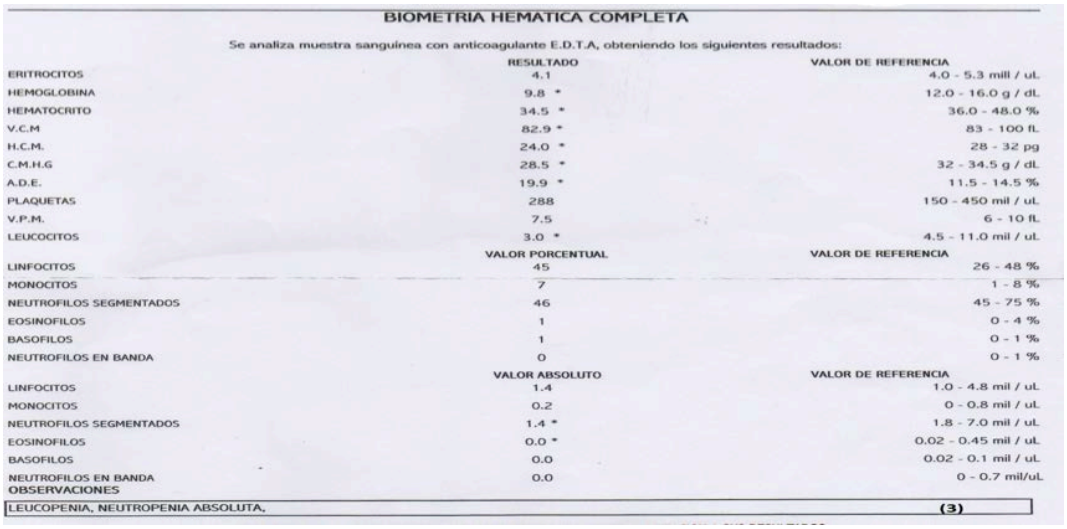

BIOMETRIA HEMATICA COMPLETA

Se analiza muestra sanguínea con anticoagulante E.D.T.A, obteniendo los siguientes resultados:

	RESULTADO	VALOR DE REFERENCIA
ERITROCITOS	4.1	4.0 - 5.3 mill / uL
HEMOGLOBINA	9.8 *	12.0 - 16.0 g / dL
HEMATOCRITO	34.5 *	36.0 - 48.0 %
V.C.M	82.9 *	83 - 100 fL
H.C.M.	24.0 *	28 - 32 pg
C.M.H.G	28.5 *	32 - 34.5 g / dL
A.D.E.	19.9 *	11.5 - 14.5 %
PLAQUETAS	288	150 - 450 mil / uL
V.P.M.	7.5	6 - 10 fL
LEUCOCITOS	3.0 *	4.5 - 11.0 mil / uL
	VALOR PORCENTUAL	VALOR DE REFERENCIA
LINFOCITOS	45	26 - 48 %
MONOCITOS	7	1 - 8 %
NEUTROFILOS SEGMENTADOS	46	45 - 75 %
EOSINOFILOS	1	0 - 4 %
BASOFILOS	1	0 - 1 %
NEUTROFILOS EN BANDA	0	0 - 1 %
	VALOR ABSOLUTO	VALOR DE REFERENCIA
LINFOCITOS	1.4	1.0 - 4.8 mil / uL
MONOCITOS	0.2	0 - 0.8 mil / uL
NEUTROFILOS SEGMENTADOS	1.4 *	1.8 - 7.0 mil / uL
EOSINOFILOS	0.0 *	0.02 - 0.45 mil / uL
BASOFILOS	0.0	0.02 - 0.1 mil / uL
NEUTROFILOS EN BANDA	0.0	0 - 0.7 mil/uL

OBSERVACIONES

LEUCOPENIA, NEUTROPENIA ABSOLUTA. (3)

Sixth scan is done on May 27, 2014. Client is asymptomatic and provides tests dated April 2014 (Image 4). The following pairs were found:

Biomagnetic Pair Scanning Technique - Scan 6 (Bioenergetics)

	Negative (-)	Positive (+)	DMP
BP 1	Right Kidney	Left Parietal	2cm
BP 2	Stomach	Thymus	2cm
BP 3	Post pineal	Bladder	2cm
BP 4	Mesenterio	Mesenterio	2cm
BP 5	Scapula	Scapula	2cm
BP 6	Kidney	Kidney	2cm
BP 7	Quiste Mediastino		2cm

Table 6 Taken from office visit

Seventh scan is done on June 9th, 2014. Client is asymptomatic and the following pairs were found:

Biomagnetic Pair Scanning Technique - Scan 7 (Bioenergetics)

	Negative (-)	Positive (+)	DMP
BP 1	Bladder	Bladder	2cm
BP 2	Left shoulder	Cardias	2cm
BP 3	Cardias	Appendix	2cm

Table 7 Taken from office visit

Image 4 Client's tests

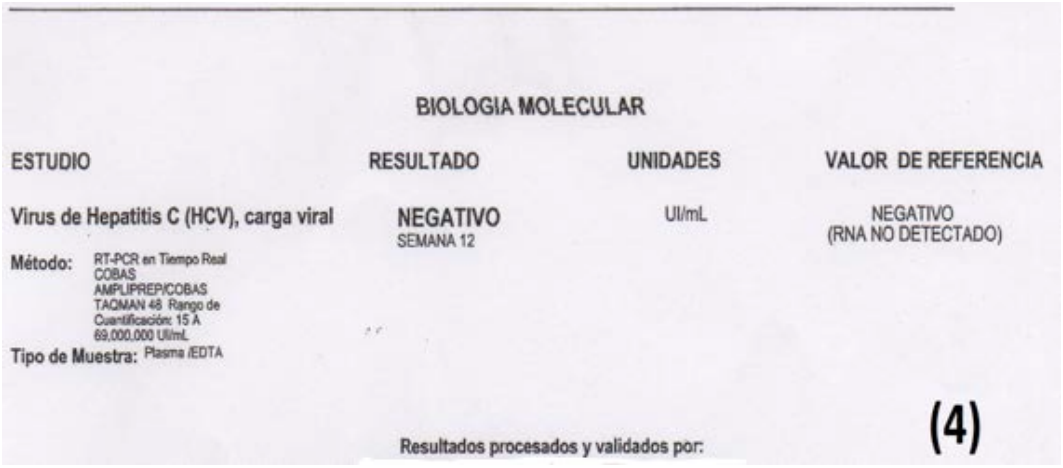

BIOLOGIA MOLECULAR

ESTUDIO	RESULTADO	UNIDADES	VALOR DE REFERENCIA
Virus de Hepatitis C (HCV), carga viral	NEGATIVO SEMANA 12	UI/mL	NEGATIVO (RNA NO DETECTADO)

Método: RT-PCR en Tiempo Real COBAS AMPLIPREP/COBAS TAQMAN 48 Rango de Cuantificación: 15 A 69,000,000 UI/mL

Tipo de Muestra: Plasma /EDTA

Resultados procesados y validados por:

(4)

Eighth scan is done on July 1st, 2014. Tests have been done and client resumes interferon alpha- 2A intake. The following pairs were found:

Biomagnetic Pair Scanning Technique - Scan 8 (Bioenergetics)

	Negative (-)	Positive (+)	DMP
BP 1	Supraspinatus	Supraspinatus	2cm
BP 2	Deltoid	Deltoid	2cm
BP 3	Carina	Carina	2cm
BP 4	Thoracic cyst		2cm

Table 8 Taken from office visit

Ninth scan is done on July 14th, 2014. Client is experiencing dizziness and weakness once more upon resuming interferon. Reports the presence of pruritus on the left shoulder and provides the results of the tests mentioned at the previous session (Images 5 & 6). The following pairs were found:

Biomagnetic Pair Scanning Technique - Scan 9 (Bioenergetics)

	Negativo (-)	Positivo (+)	DMP
PB 1	Parietal	Parietal	2cm
PB 2	Oído	Oído	2cm
PB 3	Carina	Carina	2cm
PB 4	Colon descendente	Colon descendente	2cm
PB 5	Quiste lumbar		2cm

Table 9 Taken from office visit

Image 5 Client's tests

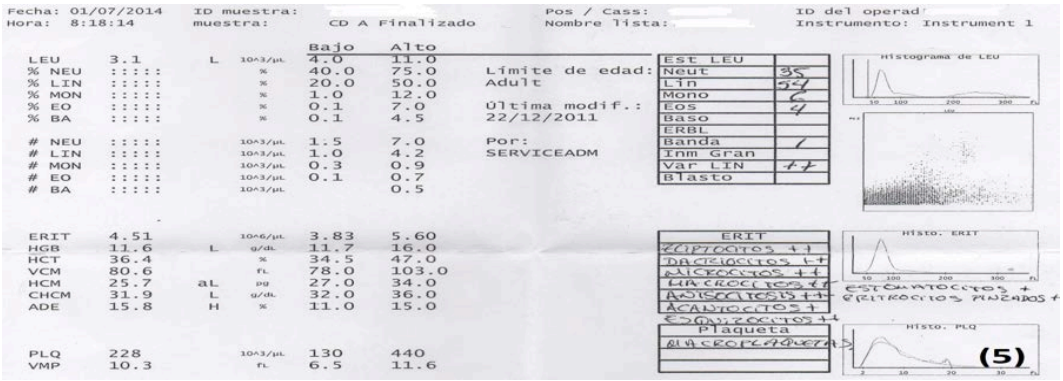

David Goiz Martínez1*† and Mario Salinas Soto1,2

Image 6 Client's tests

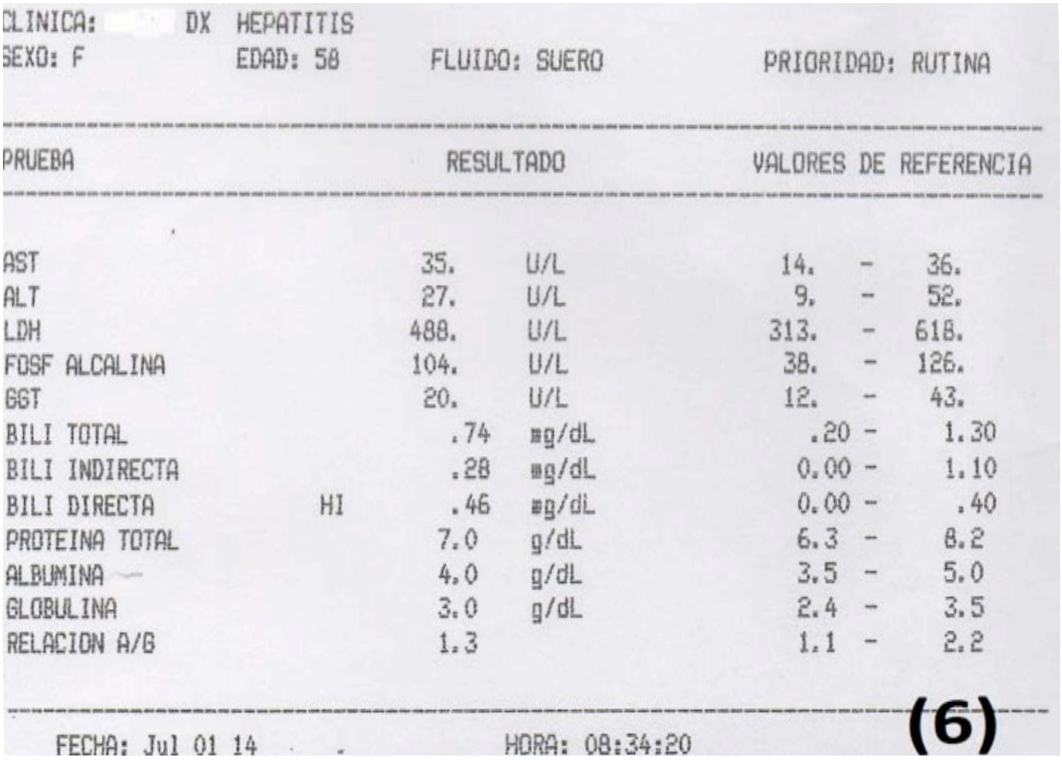

CLINICA: DX HEPATITIS
SEXO: F EDAD: 58 FLUIDO: SUERO PRIORIDAD: RUTINA

PRUEBA		RESULTADO		VALORES DE REFERENCIA
AST		35.	U/L	14. - 36.
ALT		27.	U/L	9. - 52.
LDH		488.	U/L	313. - 618.
FOSF ALCALINA		104.	U/L	38. - 126.
GGT		20.	U/L	12. - 43.
BILI TOTAL		.74	mg/dL	.20 - 1.30
BILI INDIRECTA		.28	mg/dL	0.00 - 1.10
BILI DIRECTA	HI	.46	mg/dL	0.00 - .40
PROTEINA TOTAL		7.0	g/dL	6.3 - 8.2
ALBUMINA		4.0	g/dL	3.5 - 5.0
GLOBULINA		3.0	g/dL	2.4 - 3.5
RELACION A/G		1.3		1.1 - 2.2

FECHA: Jul 01 14 HORA: 08:34:20 (6)

Clinical diagnosis
1 Hepatitis C
2 Seasonal Influenza
3 Allergic reaction at test

Discussion of the clinical case
Patients with this diagnosis usually experience a moderate progression of the aforementioned symptoms. The base test on this case showed hepatitis C. Unfortunately in these cases, following treatment is difficult due to varying results which are an important factor to consider when gauging the value of Biomagnetism when treating this pathology..

Information about the author
1.-Bioenergetics Department, CIBM. 2.-Medical Biomagnetism Department, CIBM, Insurgentes 1865, Delegación Gustavo y Madero, México Distrito Federal CP 07020. Telephone number 57819995, drdavidgoiz@biomagnetism.biz.

Acknowledgements
We would like to thank Dr. Isaac Goiz Durán for all the knowledge he has shared with humanity during the last 26 years, since his discovery of the Biomagnetic Pair in 1988.

References:

David Goiz Martínez1*† and Mario Salinas Soto1,2

1. Alter Mj. Epidemiology of hepatitis C virus infection. World J. Gastroenterol 2007; 13:2436-2441.
2.- American Gastroenterological Association Medical Position Statement on the Management of Hepatitis C. Gastroenterology 2006; 130:225-230.
3.- Berenguer M. Treatment of chronic hepatitis C in hemodialysis. Hepatology 2008; 48: 1690-1699.
4.- Berg t Weich V. Teuber G, et al. individualized treatment strategy according to early viral kinetics in hepatitis C virus type 1-infected patients. Hepatology 2009;50: 369-377.
5.- Chevalie S Pawlotsky JM. Hepatitis C virus virology, diagnosis and management of antiviral therapy. World J Gastroenterol 2007;13:2461-2466.
6.-Chou R Clark EC Helfand M. Screening for hepatitis C virus infection:a review of the evidence for the U.S. preventive services task force ann intern med. 2004; 140:465-479.
7.- Cisneros Garza Le Avendaño Reyes M Cortés Ramírez JF, et al. Guías Clínicas de diagnóstico y tratamiento de hepatitis C Epidemiología (Clinical guides for diagnosis and treatment of Hepatitis C Epidemiology). Rev. Gastroenterología México 2007;72:177-178.
8.- Brujine J Buster EH, Gelderblom HC, et al. treatment of chronic hepatitis C virus infection- Dutch national guidelines. Neth J med. 2008;66:311-22.
9.-Dehesa Violante M Aguirre J Dávila Cárdenas B, et al. Guías clínicas de diagnóstico y tratamiento de hepatitis C. Diagnóstico (Clinical guides for diagnosis and treatment of Hepatitis C Diagnosis) Rev. Gastroenterología Mex. 2007;72:179-180.
10.-Diago M. tratamiento de la infección por el virus de la hepatitis C. Estado actual y perspectivas (Treatment of infection caused by Hepititis C virus and perspectives). Gastroenterología 2008;31:596-605.
11.- Fassio e, Schroder T, et al. Conclusiones del Consejo Argentino Hepatitis c 2007 (Conclusions of the Argentinian Hepatitis Counsel). Acta Gastroenterol Latinoam 2008;38:56-74.
12.- Fried MW side effects of the therapy of hepatitis C and their management. Hepatology. 2002,36:s237-s244.